

# Platelet-Rich Plasma and Resorbable Membrane for Prevention of Periodontal Defects After Deeply Impacted Lower Third Molar Extraction

Gilberto Sammartino, MD,\* Mariano Tia, MD,†  
Eva Gentile, MD,‡ Gaetano Marenzi, MD,§ and  
Pier Paolo Claudio, MD, PhD||

**Purpose:** The extraction of deeply included third molars may cause multiple periodontal defects at the distal root of the second molar. Platelet-rich plasma (PRP) is a material containing autologous growth factors, which may be used in repairing and preventing periodontal complications at the distal root of the second molar adjacent to the extracted third molar. We have previously analyzed the effects of autologous PRP on periodontal tissues after extraction of the third molar in 18 young patients. In the current study, we investigated the clinical effects of a resorbable collagen membrane of porcine origin (Bio-Gide; Geistlich Biomaterials, Wolhusen, Switzerland) associated with PRP on bone regeneration after surgical avulsion of the inferior third molars in mesio-horizontal inclusion in comparison with the use of PRP alone.

**Materials and Methods:** Inclusion criteria were the presence of a pocket distal to the mandibular second molar with a probing depth greater than or equal to 7.5 mm and a probing attachment level greater than or equal to 6 mm, and a postextraction defect presenting with the vestibular and lingual cortical bone intact.

**Results and Conclusions:** We show that although clinical results from the comparison of PRP alone versus PRP and resorbable membrane can be considered similar, from a histologic point of view, the association of PRP to Bio-Gide membrane showed earlier signs of bone maturation but not a higher grade of bone regeneration.

*This is a US government work. There are no restrictions on its use. Published by Elsevier Inc on behalf of the American Association of Oral and Maxillofacial Surgeons.*

*J Oral Maxillofac Surg 67:2369-2373, 2009*

Periodontal complications at the level of the distal root adjacent to the second molar after the extraction of a deeply impacted lower third molar have been previously reported.<sup>1-5</sup> In these cases the use of platelet-rich plasma (PRP) demonstrated its effectiveness in the reduction of probing depth and in probing attachment level gain after only 12 weeks from the surgical removal of the included third molar.<sup>1</sup> The purpose of this study was to address whether among patients with impacted third molars the use of PRP in association with a resorbable membrane could lead to

better periodontal regeneration when compared with the use of PRP alone.

## Materials and Methods

### PATIENT SELECTION

The clinical study was conducted in a randomized, single-blind fashion at the Department of Odontostomatologic and Maxillofacial Sciences of the University of Naples "Federico II" in Italy between January 2006 and December 2007. We selected 18 patients, 9 male

\*Professor, Dipartimento di Scienze Odontostomatologiche Maxillofacciali, Università di Napoli, "Federico II," Italy.

†Researcher, Dipartimento di Scienze Odontostomatologiche Maxillofacciali, Università di Napoli, "Federico II," Italy.

‡Assistant Professor, Dipartimento di Scienze Odontostomatologiche Maxillofacciali, Università di Napoli, "Federico II," Italy.

§Researcher, Dipartimento di Scienze Odontostomatologiche Maxillofacciali, Università di Napoli, "Federico II," Italy.

||Associate Professor, Department of Biochemistry and Microbiology and Department of Surgery, Joan C. Edwards School of Medicine, Marshall University, Huntington, WV.

Address correspondence and reprint requests to Dr Claudio: Department of Biochemistry and Microbiology and Department of Surgery, Joan C. Edwards School of Medicine, Marshall University, Huntington, WV 25755; e-mail: [claudiop@marshall.edu](mailto:claudiop@marshall.edu)  
This is a US government work. There are no restrictions on its use.  
Published by Elsevier Inc on behalf of the American Association of Oral and Maxillofacial Surgeons

0278-2391/09/6711-0008\$36.00/0

doi:10.1016/j.joms.2009.04.093

and 9 female, between the ages of 21 and 25 years; all selected patients were nonsmokers, with bilateral mandibular third molar inclusion in mesio-horizontal position. The 36 cases of dental inclusion were selected for a split mouth approach study. Each patient was treated using 2 different therapeutic approaches, thereby yielding 2 different groups, a control group and a study group, each comprising 18 cases. In the study group, the alveolar cavity was filled with PRP that was covered with a resorbable membrane. The alveolar cavities of the control group were treated with PRP alone. Inclusion criteria included the presence of a pocket that was located distally to the second mandibular molar with a probing depth greater than or equal to 7.5 mm and a probing attachment level greater than or equal to 6 mm. Furthermore, the postextraction defect needed to present with the vestibular and lingual cortical bone intact (that is, not damaged during surgery). The exclusion criteria included systemic diseases, a compromised immune system, and a platelet count less than 150,000/mm<sup>3</sup>, allergies or hypersensitivity to drugs, antibiotics, anti-inflammatories, bisphosphonates, and cortisone medication for the 12-month period before surgery. All patients signed an informed consent before participating in the study, which was reviewed and approved by "Federico II" University's Institutional Review Board.

### Preoperative Therapy and Preparation of Platelet-Rich Plasma

Before surgery, all patients received oral hygiene instructions to reach an O'Leary plaque index that was less than or equal to 25%.<sup>6</sup>

A 40-mL quantity of blood was drawn from each patient and collected in 4 Vacutainer tubes (Vacutainer; Becton Dickinson, East Rutherford, NJ) containing a 10% trisodium citrate anticoagulant solution. The tubes containing the blood were placed in a centrifuge device at 1,200 rpm for 15 minutes, after which we obtained the separation of 3 fractions: platelet-poor plasma (PPP) on top, PRP in the middle, and red blood cell fraction at the bottom. A 2-mL quantity of the top layer corresponding to PPP was removed for each of the 4 tubes with a Pasteur pipette and discarded. The PRP was collected from each tube, together with 1 to 2 mm of the red blood cellular fraction to ensure that the largest and newest platelets were collected.

### Preoperative Measurements

On all patients, we performed an orthopantomography and endoral radiography using the Rinn alignment system. We evaluated the plaque index<sup>7</sup> as well

as the gingival bleeding index<sup>8</sup> immediately before surgery. The plaque and gingival indexes were then evaluated at 12 and 18 weeks after the surgery to allow for the proper healing of the treated sites.

Measurements of probing depth, probing attachment level, and gingival recession were made using cold resin to obtain a reproducible and accurate measurement of the periodontal defect by the distal surface of the second molar.

The measurements were performed using a Marquis periodontal probe in 3 different positions for all the mandibular second molars (distovestibular, distal, and distolingual). Probing depth, probing attachment level, and gingival recession were assessed at 12 and 18 weeks so as not to interfere with the healing process of the treated sites.

### Surgical Procedure

After administration of locoregional anesthesia, a full-thickness mucoperiosteal flap was raised for the extraction of the third molar. The flap incision extended from the vestibular side of the retromolar trigon to the second molar, corresponding to its distolingual cuspid. The incision continued vestibularly around the intrasulcular surface of the second molar. We then proceeded by making an additional cut distally to the papilla between the first and second molars, on a 45° angle, which extended vestibularly for 2 to 3 cm. We first performed an osteotomy using a Lindemann burr under constant irrigation, followed by an odontotomy using a diamond burr.

After the extraction of the included third molar, we prepared the residual bone cavity and proceeded with scaling the root surface of the second molar, which was carefully smoothed out using manual instruments.

In 18 cases, the bone cavity was filled using an association of PRP and a 25 × 25 mm resorbable collagen membrane of porcine origin (Bio-Gide; Geistlich Biomaterials, Wolhusen, Switzerland), and in the other 18 control cases the bone cavity was filled with PRP alone.

Coagulation of the PRP was obtained by adding 1 mL batroxobin (Botropase, Ravizza, Italy) and 1 mL of 10% gluconate of calcium 446 mEq (Fisiopharma, Palomonte, Italy), which was shaken in a sterile tube for approximately 30 seconds to obtain, within approximately 1 minute, a gel to be applied to the bone defect walls and to the planed root surface of the second molar.

In the study cases in which a membrane was used, this was prepared according to the manufacturer's instructions. The membrane was fixed to avoid mobility caused by mechanical forces, which is a factor negatively influencing bone healing. The membrane was adapted to the defect, making sure that the membrane

was beyond the defect by at least 4 mm on the vestibular and lingual sites. The membrane was then covered with the flap, making sure that it was not stretched.

In all cases, we used 4-0 Ethilon monofilament sutures to stitch the flap and removed them after 10 days. The patients were given antibiotics (amoxicillin and clavulanic acid every 12 hours for 8 days), oral anti-inflammatory treatment (ibuprofen 800 mg every day for 3 days), and 0.12% chlorhexidine gluconate rinses every 12 hours for 10 days. Oral hygiene was assessed and supportive periodontal therapy was provided for all patients at 2, 4, and 6 weeks after surgery.

**Re-Entry Procedures**

We performed an orthopantomography and control endoral radiography using the Rinn alignment system after 12 and 18 weeks to assess the healing of the treated sites on all patients. In all sites treated either with PRP and membrane or the control cases treated with PRP alone, bone biopsies were performed 12 weeks after surgery. Biopsy samples that measured 0.5 mm at the center of the treated area were fixed in 10% buffered formalin, demineralized with chloridric acid/formic acid for 48 hours, decalcified in nitric acid, and embedded in paraffin. Sections of the sample of 5 μm in thickness were then stained with hematoxylin-eosin. In this manner it was possible to assess the degree of bone regeneration that was present at the treated site. One surgeon performed all surgeries, and a second surgeon performed the clinical measurements without being aware of what therapeutic approach was used for the different sites of treatment. Results are the expression of mean values ± SD for each of the considered values. A Student *t* test was used to compare the differences between the results of the experiment and control sites.

**Results**

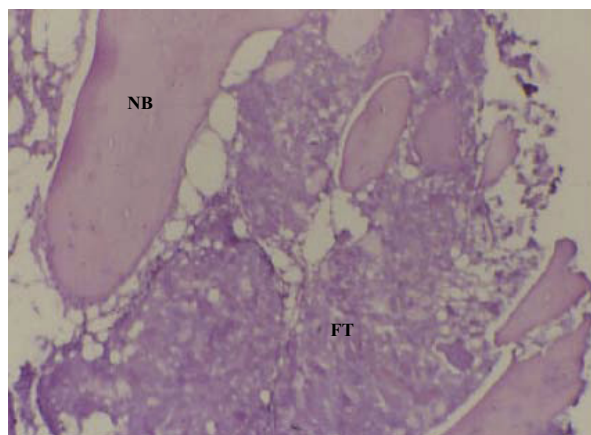
All 18 patients completed the study. For all 36 cases, we averaged the 3 results obtained by probing the distal

**Table 1. CHANGES IN PROBING DEPTH AT DISTAL SURFACE OF LOWER SECOND MOLAR (n = 18 BILATERAL CASES)**

|         | PRP         | PRP/<br>Membrane | P Value   | Difference  |
|---------|-------------|------------------|-----------|-------------|
| Initial | 8.82 ± 1.04 | 8.86 ± 0.91      | >.05 (NS) |             |
| 12 wk   | 4.14 ± 1.34 | 3.73 ± 1.23      | <.05*     | 0.41 ± 0.23 |
| 18 wk   | 3.70 ± 1.33 | 3.18 ± 1.02      | <.05*     | 0.52 ± 0.39 |

Abbreviation: NS, not statistically significant.  
\*Statistically significant.

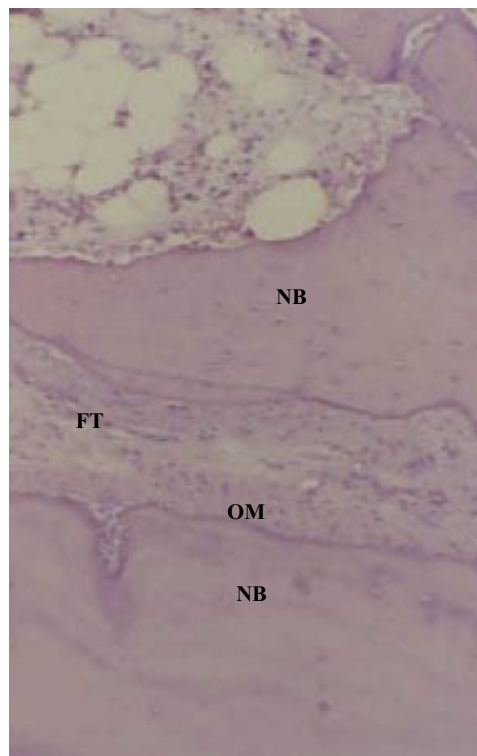
*Sammartino et al. PRP and Periodontal Defect Prevention After Molar Extraction. J Oral Maxillofac Surg 2009.*



**FIGURE 1.** Hematoxylin and eosin staining of a site treated with PRP alone demonstrating a small amount of fibrous tissue (FT) along with newly formed bone (NB) (×150 enlargement).

*Sammartino et al. PRP and Periodontal Defect Prevention After Molar Extraction. J Oral Maxillofac Surg 2009.*

surface of the second molar. All results were calculated using the mean value ± standard deviation for each of the parameters considered. The Student *t* test was used to compare the differences between the 2 groups.



**FIGURE 2.** Hematoxylin and eosin staining of a site treated with the association of PRP and Bio-Gide resorbable membrane, demonstrating the formation of newly formed bone (NB), fibrous tissue (FT), and an osteoid matrix (OM) and indicating better maturation of the newly formed bone.

*Sammartino et al. PRP and Periodontal Defect Prevention After Molar Extraction. J Oral Maxillofac Surg 2009.*

**Table 2. CHANGES IN PROBING ATTACHMENT LEVEL (n = 18 BILATERAL CASES)**

|         | PRP         | PRP/<br>Membrane | P Value   | Difference  |
|---------|-------------|------------------|-----------|-------------|
| Initial | 6.82 ± 1.05 | 6.87 ± 0.94      | >.05 (NS) |             |
| 12 wk   | 2.86 ± 1.43 | 2.43 ± 1.39      | <.05*     | 0.43 ± 0.64 |
| 18 wk   | 2.48 ± 1.32 | 1.93 ± 1.09      | <.05*     | 0.55 ± 0.49 |

Abbreviation: NS, not statistically significant.

\*Statistically significant.

Sammartino et al. PRP and Periodontal Defect Prevention After Molar Extraction. *J Oral Maxillofac Surg* 2009.

We observed a reduction in probing depth and an improvement in the probing attachment level in 17 cases treated with PRP and membrane, but improvements in the same parameters were measured also in 17 of the control cases treated with PRP alone. In 2 patients treated with PRP, or with the combination of PRP and resorbable membrane, clinical results were not satisfactory.

The decrease in probing depth in correspondence of the distal surface of the lower second molar in control patients treated with PRP alone was  $4.14 \pm 1.34$  mm at 12 weeks and  $3.70 \pm 1.33$  mm at 18 weeks. By contrast, in patients treated with PRP and resorbable membrane, the decrease in probing depth was  $3.73 \pm 0.87$  mm at 12 weeks and  $3.18 \pm 1.02$  mm at 18 weeks (Table 1). The clinical attachment gain for 12 control cases treated with PRP alone was  $2.86 \pm 1.43$  mm at 12 weeks and  $2.48 \pm 1.32$  mm at 24 weeks. In cases treated with PRP and membrane, the mean attachment gain was  $2.43 \pm 1.39$  mm at 12 weeks and  $1.93 \pm 1.09$  mm at 18 weeks.

Histologic examination of the control sites treated with PRP alone after 12 weeks from surgical dental extraction (Fig 1) showed the presence of lamellar bone tissue already mineralized, with a scarce osteoid matrix and a well-represented amount of fibrous tissue containing a high number of cells. By contrast, the histologic examination of postextractive sites treated with the association of PRP and membrane (Fig 2) showed in the newly formed bone tissue a lamellar structure that appeared denser in the presence of more fibrous tissue and osteoid matrix. The level of maturation of the regenerated bone was more represented in patients

**Table 4. CHANGES IN PLAQUE INDEX AND GINGIVAL BLEEDING INDEX (n = 18 BILATERAL CASES)**

|                         | PRP         | PRP/<br>Membrane | P Value   |
|-------------------------|-------------|------------------|-----------|
| Plaque index            |             |                  |           |
| Initial                 | 0.67 ± 0.48 |                  | >.05 (NS) |
| 12 wk                   | 0.50 ± 0.24 | 0.46 ± 0.54      | >.05 (NS) |
| 18 wk                   | 0.48 ± 0.46 | 0.44 ± 0.32      | >.05 (NS) |
| Gingival bleeding index |             |                  |           |
| Initial                 | 0.70 ± 0.63 | 0.72 ± 0.38      | >.05 (NS) |
| 12 wk                   | 0.63 ± 0.28 | 0.61 ± 0.31      | >.05 (NS) |
| 18 wk                   | 0.58 ± 0.37 | 0.56 ± 0.22      | >.05 (NS) |

Abbreviation: NS, not statistically significant.

Sammartino et al. PRP and Periodontal Defect Prevention After Molar Extraction. *J Oral Maxillofac Surg* 2009.

treated with the association of PRP and membrane than in the control patients treated with PRP alone.

Altogether these results point out that, although from a histologic point of view the patients treated with PRP and Bio-Gide membrane showed a higher level of bone maturation and better regenerative results, we could not determine an equivalent clinical and radiographic improved outcome (Table 2).

With respect to the gingival recession, we observed at both 12 and 18 weeks that there were no statistically significant differences between the 2 groups considered (Table 3). Finally, no statistically significant differences were observed between the 2 groups in terms of plaque index or gingival bleeding index (Table 4).

Therefore, although we found a statistically significant difference in the values of probing attachment level and of clinical attachment gain between the 2 groups, because the use of resorbable membrane did not confer any additional clinical benefit to the reconstructive effort, these data provide no added clinical value regarding the technique.

## Discussion

Periodontal complications to the distal root of the second inferior molar after avulsion of the adjacent included third molar have been extensively studied in the past.<sup>2,5</sup> In particular, periodontal complications at the

**Table 3. CHANGES IN GINGIVAL RESSION (n = 18 BILATERAL CASES)**

|                       | PRP         | PRP/Membrane | P Value   | Difference  |
|-----------------------|-------------|--------------|-----------|-------------|
| Variation after 12 wk | 0.72 ± 0.49 | 0.68 ± 0.48  | >.05 (NS) | 0.04 ± 0.57 |
| Variation after 18 wk | 0.78 ± 0.37 | 0.75 ± 0.51  | >.05 (NS) | 0.03 ± 0.68 |

Abbreviation: NS, not statistically significant.

Sammartino et al. PRP and Periodontal Defect Prevention After Molar Extraction. *J Oral Maxillofac Surg* 2009.

distal root surface adjacent to the second molar that follow an impacted lower third molar in deep extraction have been described to be related to the age of the patient and the angulation and severity of the inclusion.<sup>2-5</sup>

The use of PRP was shown to be a useful tool in aiding periodontal and bone regeneration *in vivo* because of the high content of growth factors.<sup>9-15</sup>

We have previously investigated the use of PRP in bone regeneration after extraction of impacted third molars.<sup>1</sup> In this study we used the Bio-Gide membrane for its excellent biocompatibility because the purified collagen of porcine origin is similar to that of human origin and therefore is well accepted by the human organism. In addition, it has been preferred for its resistance to traction and tear, and for the timeline of its resorption (4 to 6 months), meaning that it does not necessitate a second intervention for removal.<sup>16,17</sup>

In the current study, the platelet gel proved to be a material of sufficient consistency to sustain and adapt to the resorbable membrane, avoiding the collapse of the membrane inside the postextractive bone cavity. In our opinion this characteristic was very important for the regenerative process itself because it allowed earlier bone maturation, which was demonstrated by histology.

We compared, with a split mouth technique, the bone regenerative capacity of PRP associated with a resorbable membrane to PRP alone (as a control) after the extraction of deeply impacted lower third molars. The aim of this study was to evaluate whether the use of PRP in association with a resorbable membrane could improve the periodontal regenerative outcome when compared with the use of the PRP alone. Interestingly, although clinical results from the comparison of PRP alone versus PRP and resorbable membrane can be considered similar, from a histologic point of view the association of PRP to Bio-Gide membrane showed earlier (at 12 weeks) and better bone maturation but not a higher grade of bone regeneration. Both surgical techniques demonstrated comparable periodontal conditions at the level of the lower second molar, although the association of resorbable membrane and PRP allowed faster bone maturation. In essence, the PRP gel proved to be an autologous biomaterial with useful features that allowed efficient postextractive bone defect filling and good adaptation of the resorbable membrane.

In the future, it will be necessary to perform further histomorphometric studies on the ultrastructural characteristics of the periodontal attachment originated at the distal surface of the second molar to evaluate *in vivo* the efficacy of PRP on the regeneration of periodontal tissues.

In conclusion, the present study shows that platelet-rich plasma, in association with resorbable collagen

membrane used to prevent periodontal complications that may follow the extraction of deeply impacted lower third molar, yields only a limited increase in bone regeneration when compared with the use of PRP alone, which ultimately cannot be considered clinically relevant. The combined use of PRP with resorbable membrane seems to favor only a more precocious maturation of the regenerated bone in the surgical site.

## References

1. Sammartino G, Tia M, Marenzi G, et al: Use of autologous platelet-rich plasma (PRP) in periodontal defect treatment after extraction of impacted mandibular third molars. *J Oral Maxillofac Surg* 63:766, 2005
2. Ash M, Costich E, Hayward J: A study of periodontal hazards of 3rd molars. *J Periodontol* 33:209, 1962
3. Kugelberg CF: Periodontal healing two and four years after impacted lower third molar surgery. A comparative retrospective study. *Int J Oral Maxillofac Surg* 19:341, 1990
4. Kugelberg CF, Ahlstrom U, Ericson S, et al: The influence of anatomical, pathophysiological and other factors on periodontal healing after impacted lower third molar surgery. A multiple regression analysis. *J Clin Periodontol* 18:37, 1991
5. Szmyd L, Hester WR: Crevicular depth of the second molar in impacted third molar surgery. *J Oral Surg Anesth Hosp Dent Serv* 21:185, 1963
6. O'Leary TJ, Drake RB, Naylor JE: The plaque control record. *J Periodontol* 43:38, 1972
7. Silness J, Loe H: Periodontal disease in pregnancy. I. Correlation between oral hygiene and periodontal condition. *Acta Odontol Scand* 22:121, 1964
8. Muhlemann HR, Son S: Gingival sulcus bleeding—A leading symptom in initial gingivitis. *Helv Odontol Acta* 15:107, 1971
9. Camargo PM, Lekovic V, Weinlaender M, et al: Platelet-rich plasma and bovine porous bone mineral combined with guided tissue regeneration in the treatment of intrabony defects in humans. *J Periodontol Res* 37:300, 2002
10. de Obarrio JJ, Arauz-Dutari JI, Chamberlain TM, et al: The use of autologous growth factors in periodontal surgical therapy: Platelet gel biotechnology—Case reports. *Int J Periodontics Restorative Dent* 20:486, 2000
11. Kawase T, Okuda K, Wolff LF, et al: Platelet-rich plasma-derived fibrin clot formation stimulates collagen synthesis in periodontal ligament and osteoblastic cells *in vitro*. *J Periodontol* 74:858, 2003
12. Lekovic V, Camargo PM, Weinlaender M, et al: Effectiveness of a combination of platelet-rich plasma, bovine porous bone mineral and guided tissue regeneration in the treatment of mandibular grade II molar furcations in humans. *J Clin Periodontol* 30:746, 2003
13. Marx RE, Carlson ER, Eichstaedt RM, et al: Platelet-rich plasma: Growth factor enhancement for bone grafts. *Oral Surg Oral Med Oral Pathol Oral Radiol Endod* 85:638, 1998
14. Okuda K, Kawase T, Momose M, et al: Platelet-rich plasma contains high levels of platelet-derived growth factor and transforming growth factor-beta and modulates the proliferation of periodontally related cells *in vitro*. *J Periodontol* 74:849, 2003
15. Whitman DH, Berry RL, Green DM: Platelet gel: An autologous alternative to fibrin glue with applications in oral and maxillofacial surgery. *J Oral Maxillofac Surg* 55:1294, 1997
16. Blumenthal N, Steinberg J: The use of collagen membrane barriers in conjunction with combined demineralized bone-collagen gel implants in human infrabony defects. *J Periodontol* 61:319, 1990
17. Camelo M, Nevins ML, Schenk RK, et al: Clinical, radiographic, and histologic evaluation of human periodontal defects treated with Bio-Oss and Bio-Gide. *Int J Periodontics Restorative Dent* 18:321, 1998